

To

WITH THE AUTHOR'S COMPLIMENTS


56_v

DENTITION OF THE PALATE IN
CYNOGNATHUS.

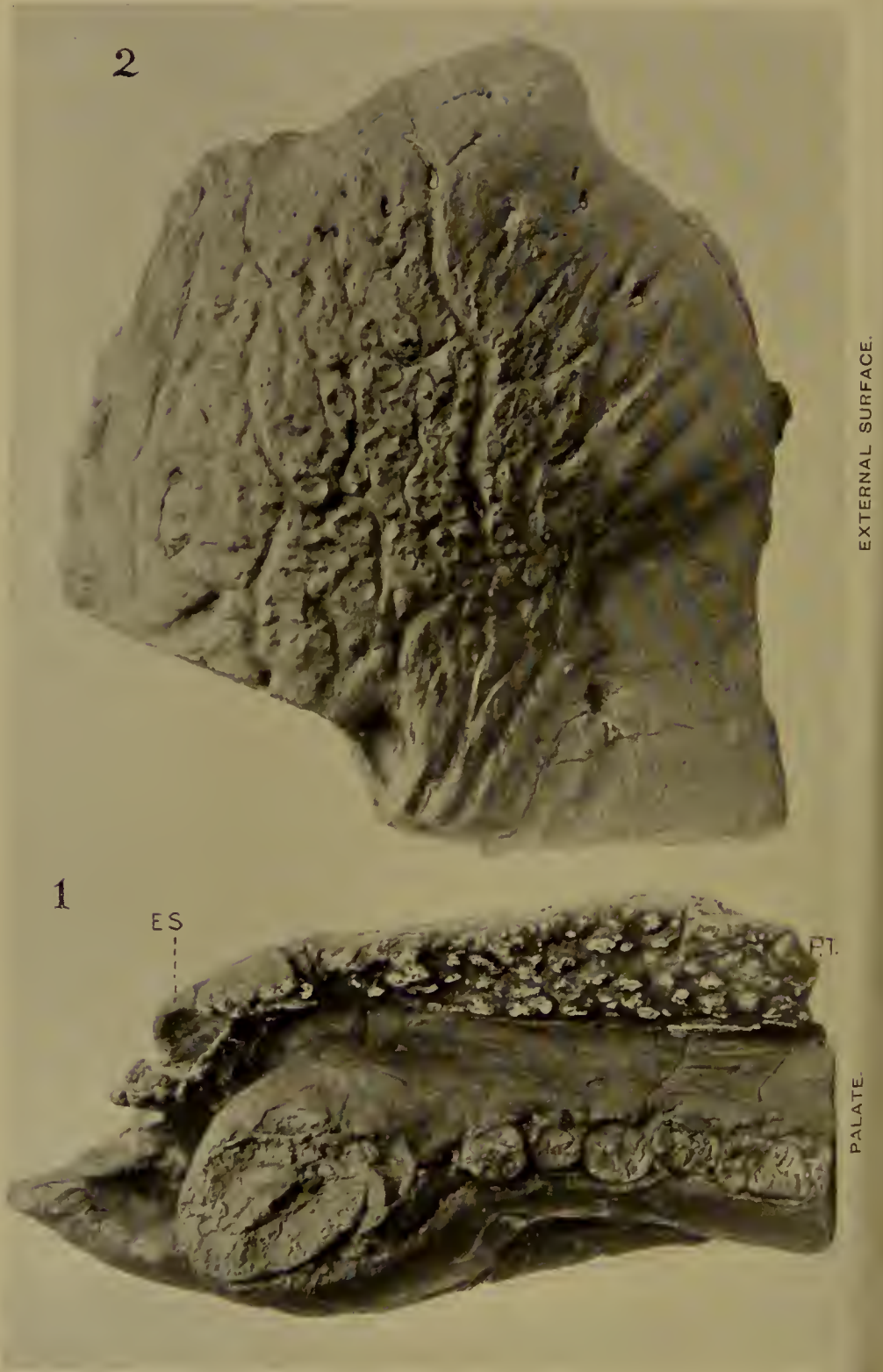
BY

PROFESSOR H. G. SEELEY, F.R.S., F.G.S.

[*Extracted from the GEOLOGICAL MAGAZINE, N.S., Decade V, Vol. V,*



LONDON: DULAU & CO., 37, SOHO SQUARE, W.



Maxillary dentition and snout-sculpture, *Cynognathus crateronotus*.

ON THE DENTITION OF THE PALATE IN THE SOUTH AFRICAN
FOSSIL REPTILE GENUS *CYNOGNATHUS*.

By Prof. H. G. SEELEY, F.R.S., F.G.S., King's College, London.

(PLATE XXIV.)

THE Cynodont reptilia from the Lower Karroo rocks of South Africa, characterized by relatively large incisors and relatively small, sharp-pointed, molar teeth, were grouped under the type genus *Lycosaurus* as Lycosauria. The removal of matrix from the palate of *Ælurosaurus* showed that in one member of the group at least the palate carries patches of teeth, each of which has the form of a small blunt flattened cone. From the fact that no Cynodont skull is available in which the mandible is free from the head, the nature of the palatal dentition is imperfectly known.

Of the new Cynodont reptilia obtained by myself from the Upper Karroo rocks in 1889, the most complete were species of *Cynognathus* (Phil. Trans. Royal Soc., B, 1895, p. 59). But these specimens, with relatively large denticulated molar teeth, all have the mandible closed upon the skull, so that the anterior part of the palate is not displayed.

In *Cynognathus crateronotus* (op. cit., fig. 9, p. 83) the palatine bones arch over the palato-nares, but as they extend backward laterally each appears to be twisted over, with a lateral bulge, to make the walls of the palato-nares behind the hard palate. The mandibular symphysis obscures the front of the palate, but it only extends posteriorly as far as the maxillary canines. No teeth were exposed upon the maxillary plates of the palate. The matrix is so intractable and the bones so friable in the figured species *C. Berryi* that no attempt can be made to expose the palate with the chisel. In this species the extremity of the snout is lost. But the weathered nasal chamber shows a vertical median plate of bone (op. cit., fig. 24, p. 124) which appears to enter into the palate, rising for some distance into the nasal chamber, where it is flanked by thin, curved plates which may represent turbinal bones. It is less than $\frac{1}{16}$ inch wide, separated

from the flat maxillary bones of the palate by vertical sutures. It appears to afford evidence that the premaxillary bones enter into the front of the hard palate, and are free from palatal teeth. The skull of *C. platyceps* (op. cit., fig. 30, p. 139) adds nothing to our knowledge of the anterior part of the palate. Only the posterior part of the median suture is exposed, dividing the concave channel of the hard palate. There are no indications of palatal teeth; but this is no evidence that such teeth did not exist, for such structures are not likely to be found unless there is reason to look for them, and they would be easily removed by the chisel without detection.

I am indebted to the generous co-operation and enthusiasm of Dr. D. R. Kannemeyer for a fragment of a right maxillary bone from Wonderboom, which has almost exactly the size, form, and aspect of the corresponding region of the jaw of *Cynognathus crateronotus*. I have removed the matrix in the Geological Laboratory of King's College, London; and the bone (Plate XXIV) shows both externally (Fig. 2) and on the palate (Fig. 1) characteristics seen in no other figured example, but confirmed by other evidence in my hands.

The maxillary bone is separated by sutures of a squamose type from the nasal bones above and the premaxillary bones in front. The vertical premaxillary sutural surface is $1\frac{2}{10}$ inch deep, flattened, $\frac{4}{10}$ inch wide, and is limited posteriorly by the large cavity for the mandibular canine, which is excavated in the skull for $1\frac{1}{4}$ inch, and made partly by the maxillary, partly by the premaxillary bone.

Above the premaxillary suture in front is a small, smooth, rounded notch, which appears to be the hinder angle of the anterior narine, between the premaxillary and nasal bones.

The maxillary bone is limited at the upper border by the strong, vertical, squamous suture with the nasal bone. This sutural surface seen on the inner aspect of the specimen is half an inch deep in front, with the depth increasing as it extends backward. The curved contour-line of junction is indicated by the maxillary bone being 2 inches deep in front and about $3\frac{1}{2}$ inches in depth at the vertical fracture behind.

Externally (Pl. XXIV, Fig. 2) the anterior and larger part of the bone is convex, both from front to back and from above downward. This convexity is only modified by a slight, shallow, wide, longitudinal concavity, extending backward from below the nasal suture towards the direction of the prefrontal bone. But inferiorly the bone contracts in width behind the canine tooth, defining the bulbous snout, so that the lower and hinder external surface is concave.

The alveolar border behind the canine tooth, seen from the side, is straight or concave in length, while in front it recedes laterally upward towards the premaxillary suture, being convex above the maxillary canine and concave in front of the mandibular canine.

The posterior fracture passes through a conspicuous, circular, pre-orbital pit in the middle depth of the bone, situated above the fourth or fifth molar tooth. It corresponds in position exactly with the sub-orbital or middle foramen seen in the maxillary bone of the type-specimen of *Cynognathus crateronotus* (op. cit., p. 72, fig. 5). Now that the matrix is removed (Pl. XXIV, Fig. 2), the fossil shows externally at $\frac{1}{10}$ inch above the alveolar border a linear succession

of four foramina corresponding in position with the bases of the roots of molar teeth. There are also three or four smaller foramina further forward, nearer the alveolar border, which have no obvious relation to dental nutrition. There are several small, scattered, vascular foramina above the diastema in advance of the maxillary canine tooth.

In the original description the external surface of the anterior bulbous part of the maxillary bone of *C. crateronotus* is only referred to as being irregular with undulating depressions and convexities. In *C. Berryi* the bone shows a finely pitted ornament of a radiating sub-crocodilian type, in advance of the sub-orbital foramen.

In this maxillary bone the ornament (Pl. XXIV, Fig. 2) consists of close-set, small bosses with concave summit-surfaces, surrounded by depressions, which are divided into groups by sub-parallel winding longitudinal canals, with vertical connecting branches. Two or three of these sinuous, vascular channels close together are below the sub-orbital foramen, one is level with it, two are above and wider apart. Some short oblique canals descend upon the convexity of the root of the canine tooth, giving that part of the bone a fluted or folded aspect. The pitted ornament is most dense in the central area above the imbedded root of the canine tooth, and is less distinct downward, forward, and upward to the nasal suture.

The maxillary bone is exceptionally strong, averaging $\frac{8}{10}$ of an inch thick at the posterior fracture, and thinning away in front and above to the squamous premaxillary and nasal edges. Its transverse width on the palate at the canine tooth is $1\frac{8}{10}$ inch, giving the snout a width of about $3\frac{1}{2}$ inches by allowing for the left maxillary.

The internal surface of the bone above the palate and below the wrinkled sutural surface for the nasal bone is smooth, convex over the oblique root of the canine tooth, and excavated concavely below and behind it, owing to the inward extension of the maxillary plate which forms the palate.

The palatal surface of the maxillary bone contracts in width behind the canine (Pl. XXIV, Fig. 1). It is $1\frac{1}{2}$ inch wide over the first molar tooth, and about $1\frac{8}{10}$ wide at the posterior fracture. Anteriorly the palatal width decreases towards the premaxillary suture.

The crowns of all the teeth, canine and molars, are broken off level with the alveolar margin of the jaw, so that no trace is preserved of the characteristic forms of the molars of *Cynognathus*. The base of the crown of the canine is slightly ovate, compressed on the inner hinder side, implanted obliquely, directed forward, downward, and outward. It is 1 inch from front to back and $\frac{7}{10}$ inch transversely. The fracture shows a small pulp cavity.

Behind the canine is the triangular area which indicates the remnant of the base of the milk or first canine, which was removed by absorption (Pl. XXIV, Fig. 1). That tooth-fragment is obscure, but may have been fractured during the life of the animal. The absence of a tooth in this position gives the jaw laterally the aspect of having a small false diastema.

The molar teeth extend backward in a line with the inner border of the canine tooth. They vary in size, but the oval roots of the first five are contained in a length of $1\frac{8}{10}$ inch. The first has a sharp

cutting-edge in front, and is rather larger than the second. The third is longitudinally oval, and the fourth and fifth are more elongated, with a laterally compressed aspect. All are crowded into close contact.

The fracture passes through the root of the sixth tooth, which is an inch deep in the jaw, and shows the anterior border of a pulp cavity, which appears to be narrow, but is closed at the base. The root is $\frac{3}{16}$ inch wide, slightly curved inward, and its termination shows a slight notch, too slight to suggest root tubercles.

The palatal surface (Pl. XXIV, Fig. 1) comprises three areas: first, the external dentigerous border described; secondly, a middle smooth longitudinal channel; and thirdly, an inner longitudinal dental armature.

The middle concavity is wide and inclined on the outer part, narrow and steep towards the inner teeth. The more flattened part is marked towards the alveolar border with a fine, impressed, longitudinal, vascular line almost like a suture, but there is no trace of sutural separation on the posterior fracture. This smooth area ascends in front of the canine tooth into the pit for the mandibular canine, by a continuous rounded surface. The mandibular canine pit is apparently triangular, $1\frac{1}{2}$ inch deep, convex over the inner side of the canine, concave on the external lateral border, and internally it is obscured a little towards the palatal armature by crushing, but was probably concave.

The smooth palatal surface is about $\frac{3}{4}$ inch wide behind the canine tooth where widest, and extends backward with a uniform width of about half an inch. Opposite the fourth and fifth molars it develops a small longitudinal ridge, and on the inner side, next the palatal armature, there is a deep narrow groove, which is prolonged upward as a cleft or canal as though the palatal plate of the maxillary had originally been a distinct ossification from the dentary plate.

The internal portion of the palate, which carries a dental armature adapted for crushing food, is wedge-shaped in form, narrow in front between the canine teeth, widening posteriorly to fully half an inch at the posterior fracture. On the inner margin it forms a strong dental ridge, but the rest of the plate is inclined outward, so that its thickness diminishes towards the smooth channel already referred to. This armature has a certain resemblance to the tooth-plates of *Hyperodapedon* carried upon the maxillary bones and upon the parallel palatine bones. But these tooth-plates are supported upon the maxillary bone only, like the separate teeth of Endothiodonts and Lycosaurians. This triangular dental wedge is a little injured by transverse fractures, made during movements of the rock, which have bent it slightly outward at both the anterior and posterior ends. The tooth-plates are supported upon a very thin palatal expansion of the maxillary bone. With this the crushing toothed armature unites without visible suture. But a small dental plate anterior to the others was not ankylosed, and is lost. Its empty socket (Pl. XXIV, Fig. 1, E.S.) next the vacuity for the mandibular canine tooth shows that it had a basal and internal support, and rested against the dental plate behind. The premaxillary bones may have extended between and above this region of the armature, but there is no evidence of those bones preserved, unless it be in the anterior internal thickening of the maxillary bone

as a wedge which thins as it extends backward supporting the palatal armature. There is no doubt that the tooth-plates met each other in the median line of the palate without any sutural union or connection between the contiguous maxillary bones other than the premaxillary bones may have given.

The inner median surface of the dental plate shows no indication of sutural separation from the opposite maxillary bone, except in the smooth base of the empty anterior socket.

This inner surface of the plate is even, flat, with a straight baseline, prominent above the contiguous maxillary bone, curving upward as it extends forward. It is sub-parallel to the palatal dental crest; the depth of the dental plate is half an inch behind and $\frac{7}{10}$ inch in front. This internal surface shines as though covered with a film of enamel. It is finely pitted along its extent. It is roughened with the contours of constituent denticles, of which there are more than a dozen in a length of 2 inches, all welded together. Some are triangular, and their points do not reach the palatal surface, while the denticles between them, with exposed crowns, have ovate surface contours on the summit-ridge of the palate. The appearance is that of a mass of teeth densely packed in osseous union or cement.

The fractured posterior surface is less clear than might have been expected. It shows that the denticles are parallel to the inner surface and to each other. They are vertical and form about six rows, so that the individual teeth of the successive rows become shorter as they extend outward from the median line in harmony with the incline of the dental plate. The obscure sections appear to be narrow and cylindrical, but the teeth are probably of a flattened ovate form in section, like the low crowns on the palate.

On the palatal surface the denticles are arranged in parallel rows (Pl. XXIV, Fig. 1, P.T.), rising inward in successive tiers one behind another. The short, low crowns have an ill-defined appearance of being also arranged in rows which extend obliquely outward and backward. Each crown is longitudinally ovate. They vary in size and elevation and distance apart. Generally the convex surface carries one or two raised lines and a few granules which show no definite plan of arrangement. The rows of denticles become fewer as they extend forward, and at the front of the principal plate are reduced to three rows. At this point a fracture occurs, which appears to mark a second dental plate, in which all the rows are gathered up into one compressed elevated tooth-mass, about half an inch long. Its constituent denticles appear to be worn with use; they are close set, small, ovate, oblique, and comprise two parallel rows. The narrow missing tooth was shorter and may have had a similar structure.

Having this remarkable armature on the maxillary bones, it was important to re-examine the skull of *Cynognathus crateronotus* in the Natural History Museum, and Mr. Richard Hall has so far removed the matrix from the symphysial region of the mandible, with the approval of Dr. A. Smith Woodward, as to demonstrate the presence of teeth of a similar kind upon the maxillary plate of the palate, and prove that this dental armature is one of the generic characters of *Cynognathus*.

The mammalian aspect of the alveolar dentition in *Cynognathus* may have drawn attention away from the obvious resemblances between the Lycosauria with prehensile molars and the Cynognathia with cutting molar teeth. But the teeth upon the maxillary plate not only emphasise a close affinity between these divisions of the Cynodontia, but appear to indicate wider affinities of the Cynodontia with other Anomodont reptilia. Thus in *Pareiasaurus* the palate carries parallel rows of slender prehensile teeth as well as the alveolar teeth. And in the Endothiodontia the palatal dentition is fully developed though the alveolar teeth are absent. In all these types the palatal teeth preserve their individual separation from each other, and it is only in *Hyperodapedon* that any parallel is found to the way in which the palatal plate is formed in *Cynognathus*.

The posterior widening of the palatal armature by which the crowns of the denticles become separated from each other I regard as a specific character only, for in the badly preserved and crushed skull of another species the posterior expansion of the dental plate appears to be absent. If that specimen should eventually have the matrix removed sufficiently to be figured, it will show that the posterior nares were margined in this genus by broad, flattened, dental bands upon the palatine bones which have the aspect of crushing teeth, wrinkled transversely in front and somewhat tuberculate behind, but quite unworn, as might have been anticipated. The palatine dental plates can only be uncovered with the needle, and would be lost under the chisel.

EXPLANATION OF PLATE XXIV.

Maxillary dentition and snout-sculpture of *Cynognathus crateronotus*.

FIG. 1.—Palatal aspect of the right maxillary bone, showing A.T., the line of alveolar teeth, and the large canine tooth, all broken off in their sockets, also the pit for the mandibular canine tooth in front. Internal to these teeth is the smooth concave tract of the palate. P.T. indicates the long wedge of consolidated palatal teeth, narrowing in front. The crowns of these teeth have been touched with white to throw them into more distinct relief in the photograph. E.S. is the empty socket from which a tooth appears to have been lost.

FIG. 2.—External surface of the anterior half of the maxillary bone, showing the pitted and vascular sculpture. The notch in front indicates the back of the nares. Above is the line of suture with the nasal bone. The base of the canine tooth is visible on the convex middle part of the alveolar border.

The figures are of natural size.

